

## 3D Mammography

### Digital Breast Tomosynthesis

Jones Radiology is pleased to offer Digital Breast Tomosynthesis (DBT) in five metropolitan locations and several regional clinics. Our breast imaging services are supported by our team of breast radiographers, sonographers and are reported by our breast imaging radiologists.

---

#### DBT involves technology that produces a 3D image of the breast

Digital Breast Tomosynthesis (DBT) offers the potential advantage of detecting breast cancer where standard digital mammography may be limited by dense breast tissue or overlapping tissues which may hide a lesion.

DBT involves technology which produces a 3D image of the breast. The DBT takes a series of low dose x-rays through the breast at different angles. It produces a stack of images displayed as fine slices through the breast, utilising volumetric imaging with reconstructed images. VolparaDensity™ software is used in conjunction with DBT to provide an objective assessment of breast density.

#### Referral clinical criteria may include (but is not limited to):

- The patient or a family member has been diagnosed with breast cancer.
- A medical practitioner found symptoms and/or indicators suspicious for malignancy (cancer).
- The patient presented with breast tenderness and/or dense breast tissue.

---

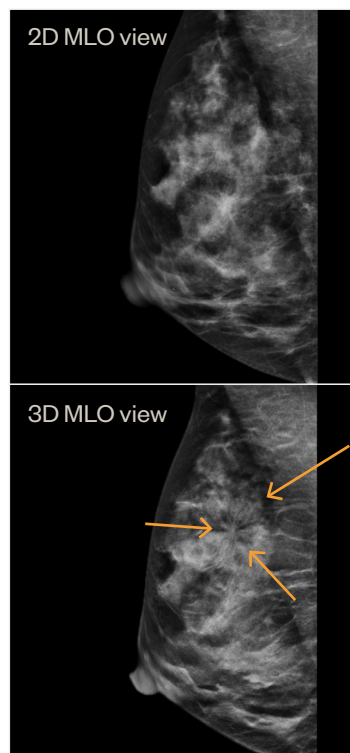
#### Key Benefits of Digital Breast Tomosynthesis

- Improved sensitivity and specificity of cancer detection in all breasts.
- Increased cancer detection in dense breast tissue above what is achievable in standard digital mammography alone.
- Reduced recall rates for assessment of benign lesions.



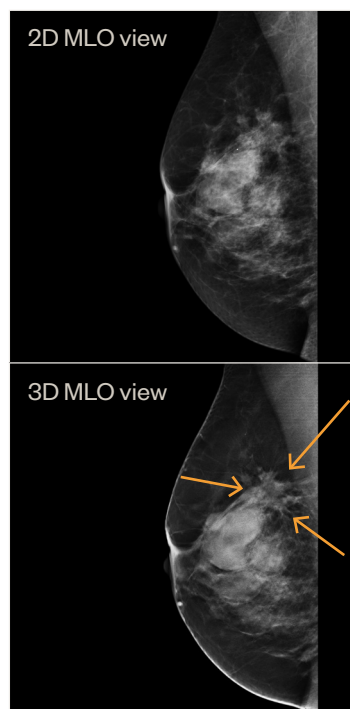
## DBT Case Study 01

<b>Clinical History</b>	• 50 year old female
	• Strong family history of breast cancer
	• Dense breasts (BIRADS D) on previous mammogram
<b>Examination</b>	• Routine screening with Tomosynthesis
<b>Findings</b>	• Routine mammogram showed normal appearances
	• Tomosynthesis showed a small stellate mass superiorly in the right breast
<b>Conclusion</b>	• 7mm, grade 1 carcinoma. Fully excised



## DBT Case Study 02

<b>Clinical History</b>	• 59 year old female
	• Lumpy breasts, new palpable lump superiorly in the right breast
<b>Examination</b>	• Routine mammogram with Tomosynthesis
<b>Findings</b>	• Routine mammogram showed multiple circumscribed masses consistent with cysts
	• Tomosynthesis showed additional stellate lesion superiorly
	• Ultrasound showed cysts at palpable lump but second solid irregular mass measuring 26mm
<b>Conclusion</b>	• Invasive lobular carcinoma



All Medical Images and Reports Available Online:

<https://online.jonesradiology.com.au/portal>

## Questions, Enquiries or Bookings:

Alice Springs Hospital 8951 7870	Gawler Health Service 8505 1599	Mt Barker Hospital 8188 7750	Pt Lincoln Hospital 7625 3647	Southern Specialist Ctr 8307 3418	Whyalla Hospital 7624 9720
Burnside Hospital 8403 3115	Modbury 8397 5851	Pt Augusta Hospital 7625 3649	337 South Toe Radiology 7100 5030	Victor Radiology Centre 7523 9895	